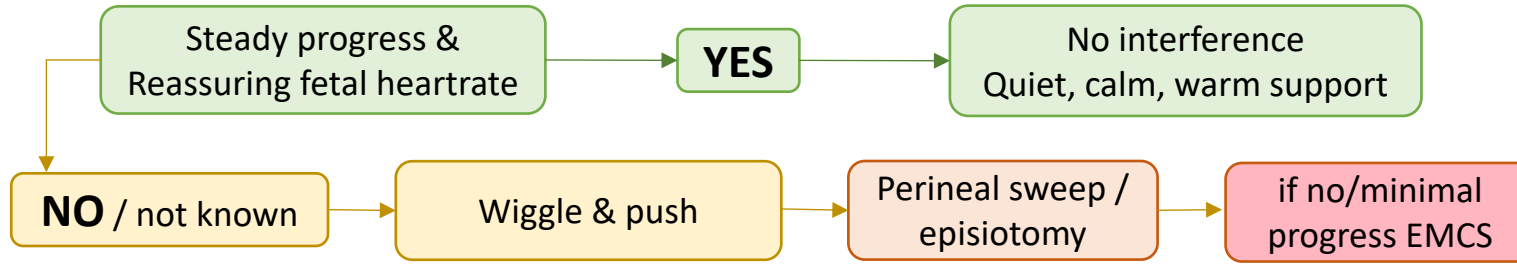
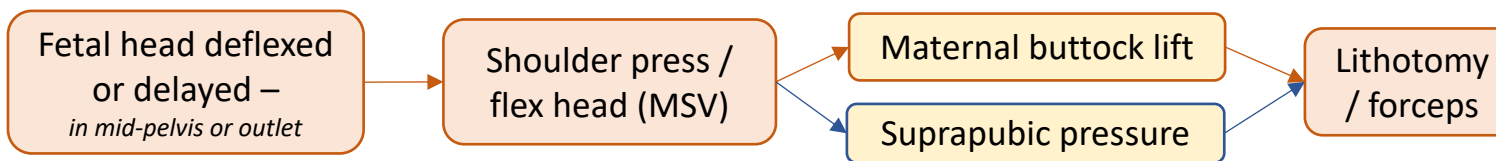
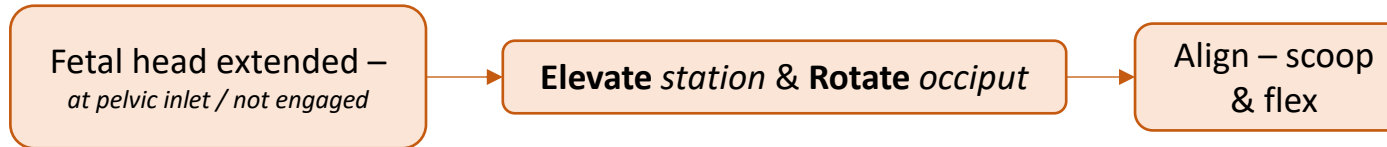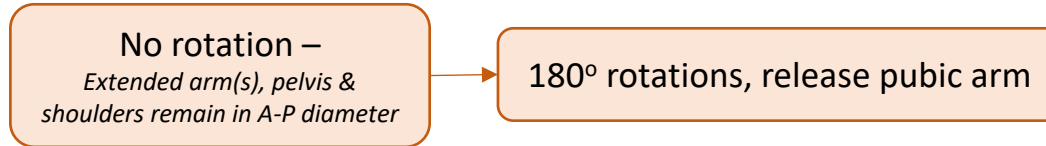
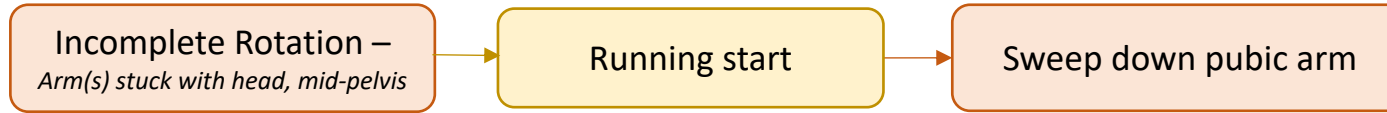


Rumping
Both buttocks/anus remain visible on the perineum between contractions



≤ 7 mins



Birth of the head

Physiological transition

DO NOT cut cord unless HR is <60 bpm and not improving

Evaluate & initiate resuscitative measures at the bedside, cord intact